

Contents lists available at [ScienceDirect](#)

Journal of Hand Surgery Global Online

journal homepage: www.JHSGO.org

Review Article

The Brazilian Perspective of WALANT in Fracture Fixation From the Hand to the Elbow

Samuel Ribak, MD, PhD, ^{*}† Celso Ricardo Folberg, MD, MSc, [‡] Jairo André de Oliveira Alves, MD [‡]^{*} Hand Surgery Service, Pontifical Catholic University of Campinas, Campinas, Brazil[†] Orthopedics Service, Hospital Nossa Senhora do Paraí, São Paulo, Brazil[‡] Orthopedic Department, Hand Surgery Team, Hospital de Clínicas de Porto Alegre, Porto Alegre, Brazil

ARTICLE INFO

Article history:

Received for publication December 19, 2021

Accepted in revised form August 9, 2022

Available online xxx

Key words:

Fractures

No tourniquet

Open reduction internal fixation

Tumescent anesthesia

WALANT

The wide-awake local anesthesia no tourniquet (WALANT) technique is currently being used by several hand surgeons. This technique enables surgeries to be performed with the patient fully awake and without a tourniquet, thus allowing the intraoperative assessment of function. The purpose of this article was to describe our WALANT techniques for metacarpal, scaphoid, distal radius, radial head, and olecranon fracture fixation with its pearls and pitfalls. The authors demonstrate their infiltration technique, detailing how to perform it using lidocaine with 1:100,000 epinephrine and 8.4% sodium bicarbonate. The authors describe where to start the tumescent anesthesia in each type of fracture described. To achieve a painless surgery under WALANT, it is crucial to administer the subcutaneous anesthetic injection around the incision site and at the periosteum to surround the entire fractured bone circumferentially. Before making the incision, the fracture site must be manipulated and the patient should not experience any pain. As a routine in every WALANT procedure, we wait at least 25 minutes to start the surgery, as this is the optimal time interval to achieve maximal vasoconstriction within the limits of tumescent anesthesia. In all operated cases, it was possible to conduct intraoperative assessment of the range of motion of the elbow, wrist, hand, and fingers, in addition to evaluating the fixation stability through active motion and ensuring earlier rehabilitation.

Copyright © 2022, THE AUTHORS. Published by Elsevier Inc. on behalf of The American Society for Surgery of the Hand. This is an open access article under the CC BY-NC-ND license (<http://creativecommons.org/licenses/by-nc-nd/4.0/>).

Osteosynthesis of hand fractures under local anesthesia or digital block has been commonly used in hand surgery for decades.¹ For more proximal fractures, the use of a tourniquet would preclude local anesthesia. With the advent of the wide-awake local anesthesia no tourniquet (WALANT) technique, more proximal fractures in the upper extremity could be addressed in a similar fashion.^{2,3}

Brazil is a country of continental dimensions, with a great diversity in services of hand surgery, including payments and costs of medical treatments, especially between the public and private sectors. Currently, many hand surgeons are using the WALANT technique, and its use is growing every day. In public hospitals in Brazil, there is a chronic lack of available locations for elective

procedures, owing to the lack of nurse and physician anesthetists, among other issues. However, surgery under local anesthesia, without sedation, an anesthesiologist, or tourniquet and with epinephrine to control the bleeding can be performed under a large-scale, outpatient scheme and with lower expenses than the conventional model.

The literature presents several reports using the WALANT technique in upper and lower limb fractures, describing the individual characteristics and advantages of the specific fractures.^{4–6} In this context, and considering the most common fractures of the upper limb below the elbow, the aim of this review was to compile and describe our WALANT techniques for metacarpal, scaphoid, distal radius, radial head, and olecranon fracture fixation with their pearls and pitfalls.

Indications and Contraindications

The advantages of using the WALANT technique are well known. Because there is no sedation or general anesthesia, there is no need

Declaration of interests: No benefits in any form have been received or will be received related directly or indirectly to the subject of this article.

Corresponding author: Samuel Ribak, MD, PhD, Hand Surgery Division, Department of Orthopedics, Pontifícia Universidade Católica de Campinas (PUC-Campinas), Rua Tangará 775, São Paulo, CEP: 06711-020, Brazil.

E-mail address: ribaksamuel@yahoo.com.br (S. Ribak).

<https://doi.org/10.1016/j.jhsg.2022.08.006>

2589-5141/Copyright © 2022, THE AUTHORS. Published by Elsevier Inc. on behalf of The American Society for Surgery of the Hand. This is an open access article under the CC BY-NC-ND license (<http://creativecommons.org/licenses/by-nc-nd/4.0/>).

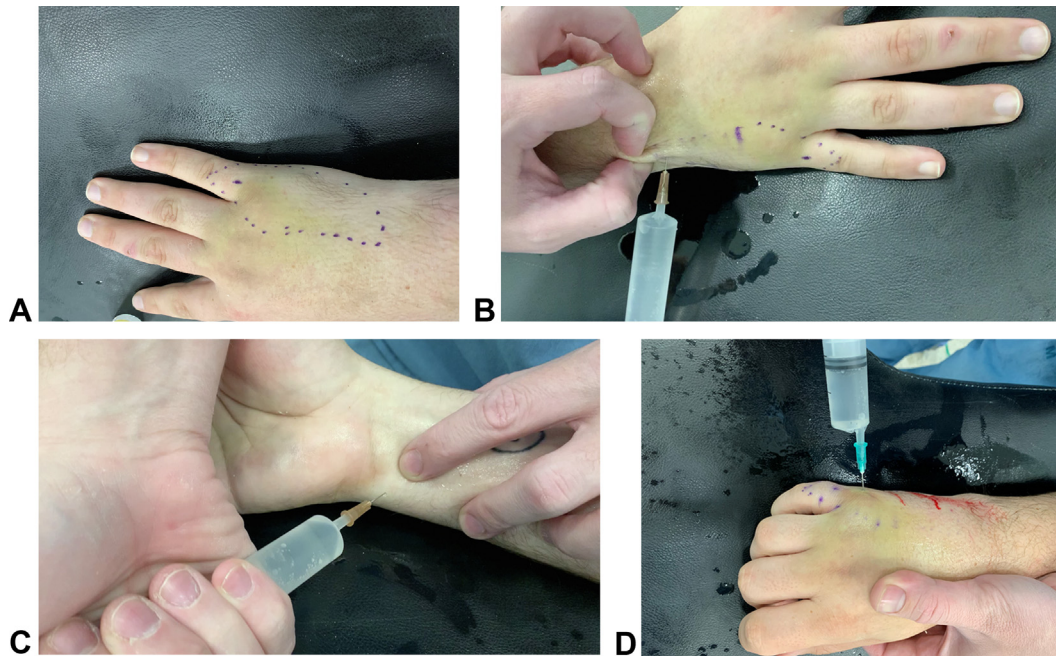


Figure 1. **A** The area for tumescent anesthesia demarcated in blue marks starting from the V metacarpal base to distal to the metacarpophalangeal joint, where the mini-incision site is marked. **B** Starting the tumescent anesthesia proximally in the demarcated area in the subcutaneous tissue around the base of the V metacarpal with a 30-gauge needle. **C** Infiltrating 3 mL of the anesthetic solution around the ulnar nerve. **D** Infiltrating 3 mL of anesthetic solution at the fracture site.

for fasting and interrupting medications before surgery (eg, anti-diabetic and anticoagulants). Moreover, the patient does not need to go to a recovery room and there are no side effects of general anesthesia, such as nausea, vomiting, and pain after waking up.⁷ Furthermore, the possibility of actively testing joint range of motion and fracture stability are other benefits of the technique.⁸ It has already been proven to be safe, efficient, and comfortable for the patients in several hand surgery articles.^{3,7,9,10} If the surgeon keeps within the limit of 7 mg/kg of lidocaine and avoids intravascular injections, the side effects are mild, if present at all.¹¹

In some cases, the reduction and fixation of fractures can be performed using minimally invasive techniques in which minimal damage to the port of entry occurs. There are savings generated by shorter hospital stay, faster recovery, and lower complication rates.^{12,13} The combination of a less invasive anesthetic technique with a less invasive surgical fixation of fractures provides a better result when both techniques are performed together.

On the other hand, although most patients are amenable to wide-awake procedures, it is our opinion that they should not be used when the patient does not agree or is not comfortable with this technique. Patients who are anxious or under stress may not tolerate a wide-awake procedure. Given that the patient will participate and stay awake during surgery, the surgeon should spend enough time explaining the entire procedure to the patient, making sure that he or she fully understands and agrees. On the other hand, it should be noted that this technique is not suited for everyone because not all surgeons appreciate interactive discussions with patients.^{14,15} If it is anticipated that the procedure will cause pain after surgery, ropivacaine or bupivacaine can be added to the anesthetic solution, providing a long-lasting effect.

Another contraindication would be peripheral vascular diseases or ischemia, which could get worse with the use of adrenaline.¹⁶ Rarely, allergy or hypersensitivity to the components of the local anesthetics may preclude the use of the WALANT technique. Fortunately, the incidence of true allergy is less than 1%.¹⁷ Other

side effects are vasovagal or “lidocaine rush,” both uncommon and transient benign side effects. If the surgeon injects the local anesthesia while the patient is laying down and explains the possible occurrence of these side effects, potential problems can be mitigated.

Technique

Fifth metacarpal neck fracture

Anesthetic solution: 40 mL of 1% lidocaine with a 1:100,000 epinephrine concentration and 4 mg of 8.4% sodium bicarbonate.

Our tumescent anesthesia begins proximal to the carpometacarpal joint always using a 30-gauge needle (Fig. 1A, B). If the surgery is simply to insert a retrograde Herbert screw through the metacarpal head, the guide wire will still extend all the way proximally to the base of the metacarpal and thus adequate analgesia proximal to the carpometacarpal joint is necessary. We continue distally with the tumescent anesthesia on the radial and ulnar sides of the metacarpal bone with a 25-gauge or 27-gauge needle (Fig. 1C). The local anesthetic can be palpated subcutaneously, and it can be seen as it expands the tissues and the skin turns white where the tumescent anesthesia has been injected (Fig. 1D). The aim is to move up to the base of the proximal phalanx. A total of 3–4 mL of the solution is injected at the fracture site and an additional 3–5 mL at the wrist to block the ulnar and/or the median nerve, depending on the fracture location. A maximum of 40 mL should be used; however, 20–25 mL is usually sufficient to cover the base of the metacarpal up to the proximal phalanx. Because local anesthesia is performed a few minutes before the procedure, the spread of the anesthetic solution is enough to not cause prolonged increase in compartment pressure.

Tips

To achieve a painless surgery under WALANT, it is crucial to administer the subcutaneous anesthetic injection around the

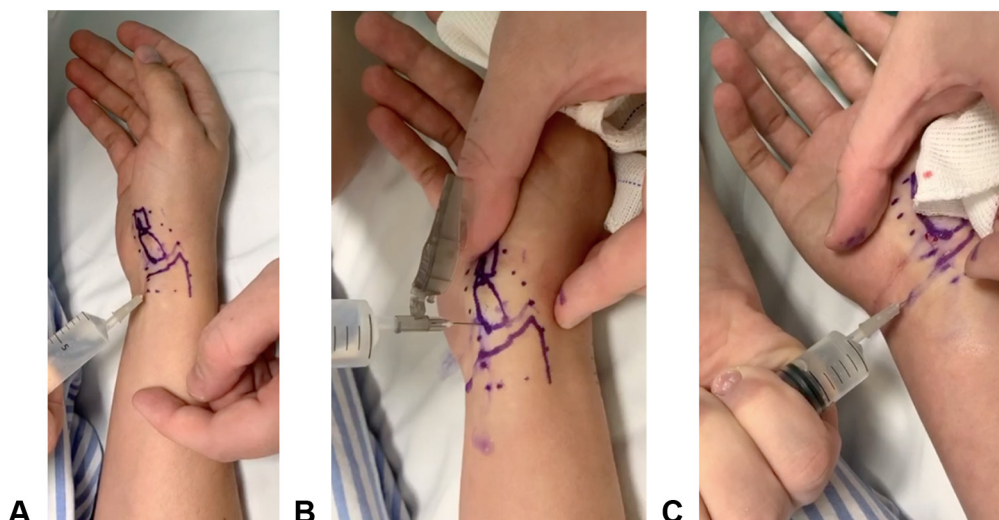


Figure 2. **A** Starting the tumescent anesthesia inside the area demarcated with the blue dots. **B** Infiltrating the scaphoid proximal pole periosteum and scaphotrapezium joint using a 25-gauge needle. **C** Injecting anesthesia around the median nerve between palmaris longus and flexor carpi radialis tendons.

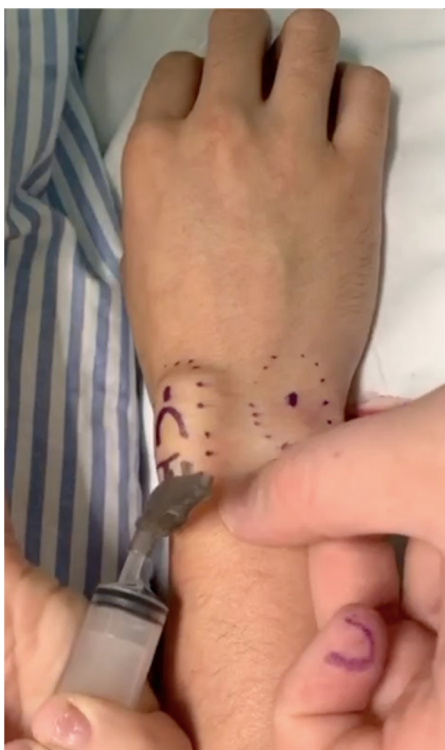

Figure 3. Tumescent anesthesia dorsally starting around Lister tubercle delineated with the marking pen (red dot).

incision site and at the periosteum to surround the entire fractured bone circumferentially. Before making the incision, the fracture must be manipulated and the patient should not experience any pain.

The patient is requested to keep their fist clenched throughout the procedure, as keeping all finger metacarpophalangeal joints flexed throughout the procedure aids in reduction and avoids rotational deformity.

The choice of the length and the width of the intramedullary headless cannulated screw used is extremely important for the success of the surgery. The length of the selected screw must

be sufficient to provide axial stability both proximal and distal to the fracture site. The width chosen must be sufficient to provide interference fit in the intramedullary canal and achieve rotational stability at the fracture site. Usually, 3.0-mm wide and 30-mm long screws are sufficient to stabilize metacarpal neck fractures. It is important that the screw provides a stable lever arm relative to the fracture, with similar lengths proximal and distal to the fracture site.

Scaphoid fracture

Anesthetic solution: 40 mL of 1% lidocaine with 1:100,000 epinephrine concentration and 4 mg of 8.4% sodium bicarbonate.

Some patients are more amenable to local anesthesia and, with less side effects (nausea, sleepiness, sore throat), it is a viable option for those patients who do not want to use a cast for several weeks but also do not want a bigger procedure. Vertically oriented fracture patterns, which are inherently more unstable, would mostly benefit from intraoperative active motion testing after scaphoid fixation.

The tumescent anesthesia is initially injected proximal to the volar wrist crease and advanced distally around the scaphoid and trapezium subcutaneously (Fig. 2A). Subsequently, 2–3 mL of the solution is injected deeper at the distal scaphoid and scaphotrapezium joint (Fig. 2B). Proximal to the wrist crease, it is possible to block the median nerve by injecting 3 mL of the solution between the palmaris longus and flexor carpi radialis tendons (Fig. 2C). Next, local anesthesia is injected on the dorsum of the wrist, starting around the Lister tubercle and then around the proximal pole of the scaphoid and laterally around the radial styloid. Finally, the radioscaphoid joint is injected with 2–3 mL of the anesthetic solution (Fig. 3).

If the surgeon plans to perform an arthroscopic assisted fixation, the radiocarpal and midcarpal portals and joints are infiltrated with 1–2 mL of the solution on each portal.

Distal radius fracture

Anesthetic solution: 60–80 mL of 0.5% lidocaine with 1:200,000 epinephrine concentration and 3 mg of 8.4% sodium bicarbonate.

Surgery can be performed with this technique in elderly patients and special patients (with arteriovenous fistulas,

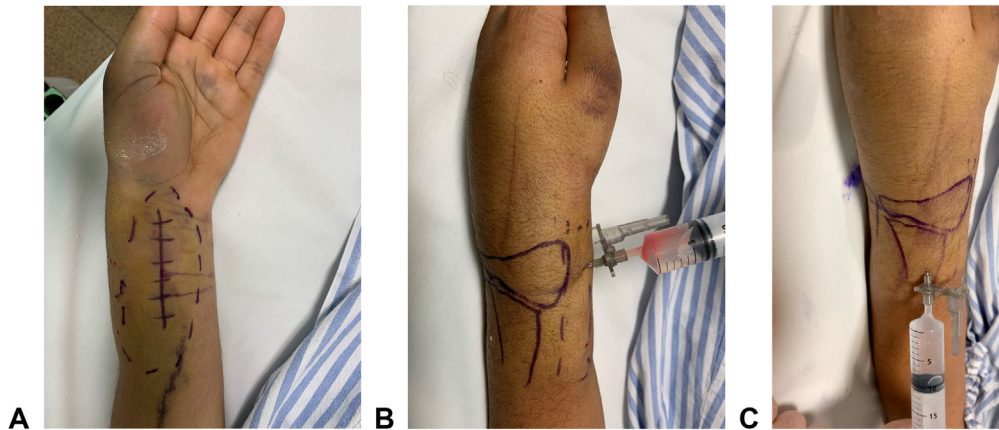


Figure 4. **A** The incision site for a volar distal radius approach is marked longitudinally and the area to be infiltrated with tumescent anesthesia is marked around the incision site with the interrupted line circumferentially. **B** The fracture focus is penetrated with a 25-gauge needle and local anesthesia is infiltrated at the site. **C** The periosteal infiltration from the lateral side must infiltrate lateral, volar, and dorsal radial periosteum.

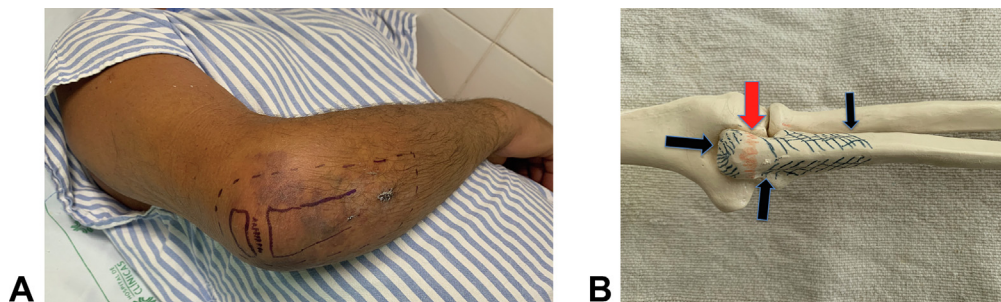


Figure 5. **A** Olecranon fracture tumescent anesthesia demarcated area with the blue interrupted line around the proximal ulna. **B** Bone model illustrating the area of proximal ulnar periosteum (blue stripes and blue dots) and simulated fracture site (red stripes and red dot) to be injected with local anesthesia.

lymphadenectomy) who cannot use a tourniquet. It is important to point out that this anesthetic technique does not exclude other procedures, such as axillary blocks. Instead, it adds options to the surgeons' repertoire.

If a volar plate is planned, the volar incision site is marked and the tumescent anesthesia is infiltrated all around the site (Fig. 4A). Next, the fracture focus is infiltrated with a 25-gauge needle (Fig. 4B). We then proceed with the periosteal block from the lateral side (Fig. 4C), infiltrating all around dorsal and volar periosteum from proximal to distal in a fan-shaped distribution and using 2–3 different skin puncture sites. We continue from the medial side and complete the periosteal infiltration. The space under the pronator quadratus muscle should also be filled with local anesthetics. This periosteal block is critical to the success of local anesthesia; thus, the surgeon must ensure that the entire radial periosteum is covered with the anesthetic solution. One must remember to take the same steps around the ulna if planning an ulnar fixation. The tip of Kirschner wires or screw guide wires protruding from a radial fixation may touch the ulna and cause pain inadvertently and that should be anticipated infiltrating the ulna if needed.

The advantages include intraoperative assessment of the range of motion of the wrist, hand, and fingers; evaluation of fixation stability through active motion; earlier rehabilitation; and allowing to observe the relationship of the volar plate with the flexor tendons (specifically the flexor pollicis longus, thus avoiding possible friction or tendon rupture due to inadequate position or when the plate is applied too distally, as described by Soong et al.¹⁸).

Not all fractures are amenable to standard volar locking plates, and some aspects of the fixation would benefit from an active range of motion testing. Sometimes this fixation needs to change due to fracture, implant or patients' characteristics (placing the plate more distally to stabilize the volar ulnar facet, for example).

Olecranon fracture

Anesthetic solution: 60–80 mL of 0.5% lidocaine with a 1:200,000 epinephrine concentration and 3 mg of 8.4% sodium bicarbonate.

We plan a 2-cm incision on the proximal ulna to approach the olecranon proximal fragment; however, the tumescent anesthesia should be injected all the way from the proximal ulna to approximately 10 cm distally because of the intramedullary screw length. The area for the tumescent anesthesia is demarcated as shown in Figure 5A. Moreover, we always infiltrate both the periosteum and the fracture site (Fig. 5B).

We start by injecting the tumescent anesthesia with a 30-gauge needle proximally and then continue in the subcutaneous layer with a 25-gauge needle. We fill the entire demarcated area with 30 mL of local anesthesia. Subsequently, the fracture site (Fig. 6A) and the periosteum of the proximal ulna (Fig. 6B) are also infiltrated all the way from the proximal to the distal border of the area planned to receive local anesthesia. It is extremely important to hold the needle close to the bone, especially proximally and medially. We palpate the ulnar nerve to ensure that the needle is far away from the nerve. Nevertheless, ulnar nerve block may occur because the

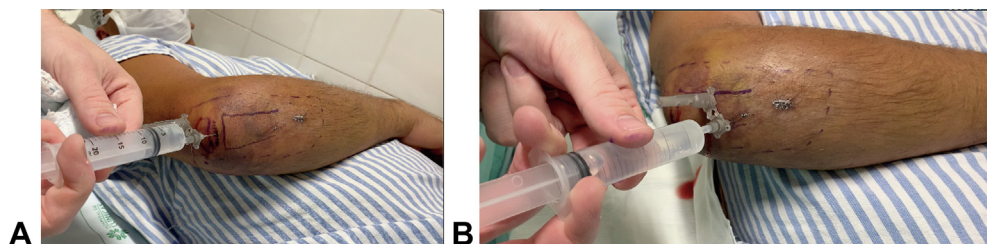


Figure 6. **A** Infiltration of an olecranon fracture site. **B** Infiltration of the proximal ulnar periosteum.

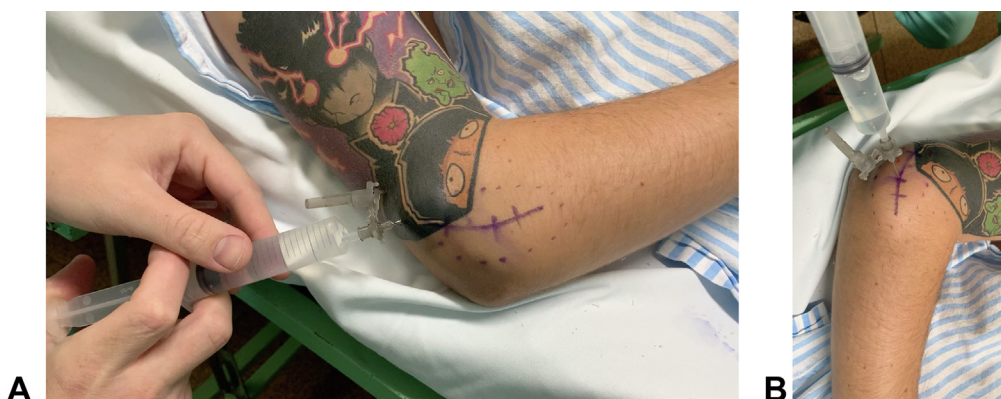

Figure 7. **A** Tumescence anesthesia inside the area demarcated with the blue dots around the incision line to approach the radial head fracture. **B** Radiocapitellar infiltration. Note the subcutaneous distension around the incision demarcated line with the infiltrative anesthesia performed before.

anesthesia infiltrated medially, and this should be explained to the patient.

The ulna has a triangular shape proximally, thus we infiltrate at least 2 bone surfaces, as shown in [Figure 5B](#). Special attention is required when filling the fracture site with local anesthesia. Approximately 20–30 mL of the solution is injected into the periosteum and fracture site. As a routine in every WALANT procedure, we wait at least 25 minutes to start the surgery, as this is the optimal time interval to achieve maximal vasoconstriction within the limits of tumescent anesthesia.¹⁹

Radial head fracture

Anesthetic solution: 40 mL of 1% lidocaine with a 1:100,000 epinephrine concentration and 4 mg of 8.4% sodium bicarbonate.

Tumescent anesthesia is initiated close to the lateral epicondyle and proceeds distally ([Fig. 7A](#)). The next step is intra-articular (radiocapitellar) infiltration with 5–10 mL of the solution ([Fig. 7B](#)). After the radial head is exposed, the ulnar notch should be infiltrated with 2–3 mL, because if the guide wire of the cannulated screw, or even the drill, touches the ulnar notch, the patient usually feels some discomfort.

Discussion

The WALANT technique is currently being used by a large number of hand surgeons. This technique enables surgeries to be performed with the patient fully awake and without a tourniquet, thus allowing the intraoperative assessment of function. Phalangeal and metacarpal fractures with rotational deformities are great examples why the need for transoperatively assessing the correction of the deformity and stability of the osteosynthesis is important.

The benefits of the technique include avoiding adverse effects of general anesthesia and the overall reduction of the surgery costs. Local anesthesia procedures are undoubtedly comparable with regional blocks in terms of safety and discharge. However, a well-performed block needs a well-trained anesthesiologist, and in Brazil we have a few that do not perform this anesthetic technique. Thus, local anesthesia performed by the surgeon is an option when the general anesthesia is the only one available.

A literature search revealed published reports about the use of WALANT technique for specific fracture surgery of the upper limb, highlighting its results and advantages. The aim of this article was to present our experiences and demonstrate our infiltration technique from metacarpal fractures in the hand to olecranon fractures at the elbow, detailing how to perform it. The tumescent anesthesia concept consists of injecting relatively large volumes of dilute neutralized lidocaine solution with epinephrine into the subcutaneous tissue, restricted to the area that will be approached. Bleeding at the surgical field can be minimized by the vasoconstriction effect of epinephrine.

Regarding the application in fractures of the metacarpal bones, Gregory et al,⁸ Xing and Tang,²⁰ Hyatt and Rhee,⁴ and Rhee²¹ mention that among the benefits of performing phalangeal and metacarpal fracture closed reduction and fixation of using the WALANT technique is reaching a complete range of motion during the intraoperative period. By requesting the patient to flex and extend the fingers, it is possible to confirm (with the aid of fluoroscopy) whether there is stability of the fracture and that there is no friction between the osteosynthesis implants and the skin or tendons. Early rehabilitation then becomes safe, resulting in faster recovery and return of function. If the fixation systems were all perfect, there should be no failure in any fracture fixation. The use of active testing, allowed by the local anesthesia, comes to walk side-by-side with a strong fixation construct.

Hyatt and Rhee⁴ noticed that the 3 most common reasons for the failure of the WALANT technique are insufficient volume of anesthetic solution, not injecting the anesthetic solution in all possible areas that needed to be addressed (either by dissection or trajectory of Kirschner wires), and inadequate waiting time between anesthesia and the beginning of the surgical procedure. Thus, the authors suggested a preferred waiting time of 20–30 minutes before starting the surgical procedure.

Regarding the use of wide-awake anesthesia in fractures of the distal end of the radius, Huang et al¹⁵ reported 60 cases of fracture of the distal extremity of the radius operated between January 2015 and January 2017. Of these, 24 patients (40%) agreed to undergo open reduction internal fixation using the WALANT technique (21 with a volar plate and 3 with a dorsal plate). During the anesthetic technique, they infiltrated 3–5 mL of 1% lidocaine in the fracture hematoma dorsally and 5–10 mL at the incision site (dorsal or volar). A waiting period of approximately 18 minutes was considered before initiating the surgical procedure. When using a volar approach, when the pronator quadratus was identified, they infiltrated 5 mL of the anesthetic solution. For the dorsal approach, an infiltration of 5 mL of the solution was performed in the region of the extensor retinaculum and in the periosteum between the third and fourth compartments of the extensor tendons. Only 1 patient did not tolerate the procedure using the WALANT technique and became anxious during subcutaneous infiltration. We reinforce here the idea that there are some patients who will not be amenable to local anesthesia for this fracture fixation surgery, and the surgeon needs to anticipate that to prevent complications. Patients who are extremely anxious and do not wish to stay awake are not ideal candidates. Assessments are occasionally incorrect and the patient does not collaborate. We recommend that the first cases performed by the surgeon are simple and should be in the presence of an anesthesiologist. In some cases, such as olecranon and distal radius, the patient has to be prepared to receive a stronger sedation or even general anesthesia (with fasting and preoperative testing as indicated).

The use of WALANT for surgical fixation of fractures can be expanded beyond the hand and wrist, and elbow fractures also present this possibility. Ahmad et al²² described a safe, easy, and efficient anesthetic technique with WALANT for olecranon fracture fixation. First, a total of 10 mL of subcutaneous local anesthesia was infiltrated using a 27-gauge needle along the predrawn midline elbow skin incision. Subsequently, another layer of local anesthesia was injected subperiosteally for the desired effect of painless surgery during reduction and plating of the olecranon fracture. The distance between each injection point was 2.5 cm. In total, 40 mL of the solution was used, with 10 mL at the subcutaneous layer and 30 mL at the subperiosteal layer. In our WALANT technique for olecranon fracture described here, we used more of the anesthetic solution, because we prefer to have more volume for this large area, even if we have to dilute lidocaine in normal saline as we did.

There is a remarkable learning curve when performing these fracture fixation surgeries under WALANT. Surgeons who wish to start operating using these techniques should start with simple cases, such as phalanges and metacarpals with little displacement, in collaborative patients. Additionally, the presence of an anesthesiologist is crucial, especially in cases in which there is a slight possibility that the need for sedation is anticipated.

Another point is the possibility of bleeding. The surgeon must be prepared to use electrocautery; however, when the solution of

lidocaine and adrenaline is administered 25 minutes prior to the procedure, this should not be a problem.

All fractures described in our study could be treated with minimally invasive techniques, preserving the fracture biology and accelerating the healing process. Minimal soft tissue aggression reduces the risk of infection and has minimal interference with the vascularization of bone fragments, preserving the vascularization of the periosteum. Adequate pain control and minimal bleeding were observed during surgery under the effect of lidocaine and adrenaline in all cases. Advantages of minimally invasive osteosynthesis techniques include reduction in postoperative pain, reduction in the inflammatory response to trauma, and a better esthetic result. There is the possibility of educating the patient during the surgery, allowing confidence in early range of motion and better rehabilitation.

References

1. Belsky MR, Eaton RG, Lane LB. Closed reduction and internal fixation of proximal phalangeal fractures. *J Hand Surg Am.* 1984;9(5):725–729.
2. Lalonde D. *Wide Awake Hand Surgery.* Thieme Publishers; 2015.
3. Lalonde D, Eaton C, Amadio PC, Jupiter JB. Wide-awake hand and wrist surgery: a new horizon in outpatient surgery. *Instr Course Lect.* 2015;64:249–259.
4. Hyatt BT, Rhee PC. Wide-awake surgical management of hand fractures: technical pearls and advanced rehabilitation. *Plast Reconstr Surg.* 2019;143(3):800–810.
5. Ahmad AA, Ikram MA. Plating of an isolated fracture of shaft of ulna under local anaesthesia and periosteal nerve block. *Trauma Case Rep.* 2017;12:40–44.
6. Ahmad AA, Yi LM, Ahmad AR. Plating of distal radius fracture using the wide-awake anesthesia technique. *J Hand Surg Am.* 2018;43(11):1045.e1–1045.e5.
7. Lalonde DH. Latest advances in wide awake hand surgery. *Hand Clin.* 2019;35(1):1–6.
8. Gregory S, Lalonde DH, Fung Leung LT. Minimally invasive finger fracture management: wide-awake closed reduction, K-wire fixation, and early protected movement. *Hand Clin.* 2014;30(1):7–15.
9. Lalonde DH. Conceptual origins, current practice, and views of wide awake hand surgery. *J Hand Surg Eur Vol.* 2017;42(9):886–895.
10. Neto PJP, de Andrade Moreira L, de Las Casas PP. Is it safe to use local anesthesia with adrenaline in hand surgery? WALANT technique. *Rev Bras Ortop.* 2017;52(4):383–389.
11. Lalonde D, Martin A. Tumescent local anesthesia for hand surgery: improved results, cost effectiveness, and wide-awake patient satisfaction. *Arch Plast Surg.* 2014;41(4):312–316.
12. Lin YC, Chen WC, Chen CY, Kuo SM. Plate osteosynthesis of single metacarpal fracture: WALANT technique is a cost-effective approach to reduce postoperative pain and discomfort in contrast to general anesthesia and wrist block. *BMC Surg.* 2021;21(1):358.
13. Huang YC, Chen CY, Lin KC, Yang SW, Tarng YW, Chang WN. Comparison of wide-awake local anesthesia no tourniquet with general anesthesia with tourniquet for volar plating of distal radius fracture. *Orthopedics.* 2019;42(1):e93–e98.
14. Lalonde D. Minimally invasive anesthesia in wide awake hand surgery. *Hand Clin.* 2014;30(1):1–6.
15. Huang YC, Hsu CJ, Renn JH, et al. WALANT for distal radius fracture: open reduction with plating fixation via wide-awake local anesthesia with no tourniquet. *J Orthop Surg Res.* 2018;13(1):195.
16. Thomson CJ, Lalonde DH, Denkler KA, Feicht AJ. A critical look at the evidence for and against elective epinephrine use in the finger. *Plast Reconstr Surg.* 2007;119(1):260–266.
17. Speca SJ, Boynes SG, Cuddy MA. Allergic reactions to local anesthetic formulations. *Dent Clin North Am.* 2010;54(4):655–664.
18. Soong M, Earp BE, Bishop G, Leung A, Blazar P. Volar locking plate implant prominence and flexor tendon rupture. *J Bone Joint Surg Am.* 2011;93(4):328–335.
19. McKee DE, Lalonde DH, Thoma A, Glennie DL, Hayward JE. Optimal time delay between epinephrine injection and incision to minimize bleeding. *Plast Reconstr Surg.* 2013;131(4):811–814.
20. Xing SG, Tang JB. Surgical treatment, hardware removal, and the wide-awake approach for metacarpal fractures. *Clin Plast Surg.* 2014;41(3):463–480.
21. Rhee PC. The current and possible future role of wide-awake local anesthesia no tourniquet hand surgery in military health care delivery. *Hand Clin.* 2019;35(1):13–19.
22. Ahmad AA, Sabari SS, Ruslan SR, Abdullah S, Ahmad AR. Wide-awake anesthesia for olecranon fracture fixation. *Hand (N Y).* 2021;16(3):402–406.